

Facial Danger Zones: avoiding serious complications in non-surgical filler injections

Dr Julian De Silva discusses facial danger zones
and how to treat and prevent serious adverse events

Abstract

Over the past decade non-surgical filler injections have become an increasingly popular treatment for soft tissue augmentation and facial rejuvenation. For the most part, these filler injections are considered relatively safe. Yet from my knowledge of case reports and conference discussions, there seems to be an increasing number of serious adverse events occurring, including loss of visual function, blindness, skin necrosis and facial scarring associated with the use of filler injections. In this article, I discuss the underlying facial anatomy and mechanism of these serious adverse events, the concept of facial danger zones, and present a discussion of both treatment and prevention of these serious adverse events.

Introduction

Soft tissue fillers are an increasingly popular treatment for soft tissue augmentation and facial rejuvenation. The American Society for Aesthetic Plastic Surgery reported approximately 13% growth in non-surgical treatments between 2012 and 2013; with non-surgical treatments making up over 80% of all treatments performed.¹ The consequences of serious adverse events can be devastating. They can include visual blindness,^{2,3,4,5,6,7,8,9,10,11} skin necrosis^{11,12,13} and permanent facial scarring.^{11,12,13} In this article I examine the concept of facial danger zones specific to facial anatomy. I discuss the facial anatomy that underlies the danger zones, and the treatment and avoidance of these complications with modified techniques. The most serious complications with non-surgical and surgical filler treatments include:

- Unilateral or bilateral visual impairment or blindness
- Skin necrosis
- Cerebrovascular event

Soft tissue filler products that have been associated with these serious adverse events include; hyaluronic acid, calcium hydroxylapatite, poly-L-lactic acid and polymethyl methacrylate, silicone and fat transfer.⁷

Facial Anatomy

Key to our understanding of how these serious adverse events occur is knowledge of the facial vascular anatomy. Anatomy of the face can be broadly defined into these five layers:

1. Skin (Epidermis and Dermis)
2. Subcutaneous fat in compartments (**Figure 1**)
3. Underlying facial muscles and SMAS (Superficial muscular aponeurotic system) (**Figure 2**)
4. Profuse anastomosis of facial vessels (**Figure 3**)
5. Skull

The arteries that branch from internal and external carotid arteries provide the vascular supply to the skin and subcutaneous tissue

of the face. The eye is vascularised by the ophthalmic artery via a branch from the internal carotid artery – called the central retinal artery (**Figure 4**). The central retinal artery is essential for normal visual function and any damage or blockage of this artery has the potential to reduce visual function within minutes. The ophthalmic artery continues in the orbit to the supraorbital and supratrochlear arteries. The supratrochlear artery lies in the areas of the corrugators and inferior anastomoses with the dorsal nasal artery. The supraorbital nerve exits the orbit in the superior orbital notch and anastomoses temporally with the superficial temporal artery. The external carotid artery lies in the lateral aspect of the neck. At the antero-inferior tragus it divides into the superficial temporal artery and the middle temporal artery. Although the larger vessels are anatomically described, there is a rich vascular anastomosis that increases the risk of an intra-arterial injection of filler with non-surgical treatments (**Figure 3**).

A further consideration is that patients who have undergone previous non-surgical or surgical treatments may have an underlying change in their anatomy and be at higher risk of a serious adverse event. This is evident for the nose where previous rhinoplasty may have injured vascular anastomosis, making non-surgical filler injections post-rhinoplasty a higher risk procedure.¹⁵

Mechanism of Serious Adverse Events

Loss of visual function occurs as a consequence of occlusion of the central retinal artery. The central retinal artery provides the principle blood supply to the key part of the eye (retina) that provides vision. If these cells are deprived of oxygen, even for a short period, they become permanently damaged leading to a irreversible loss of visual function. For this to occur there is a mechanical blockage of arterial blood flow along the central retinal artery. In this case, filler injected into the soft tissues around the periorbital areas is inadvertently injected intra-arterially (**Figure 5**) into one or more of the five facial danger zones. With sufficient pressure and volume, there is a retrograde flow of the filler along the artery via vascular anastomosis to the central retinal artery. Some of the filler product flows antero-grade into the central retinal artery, resulting in occlusion of the central retinal artery and compromised visual function. The extent of the visual function deterioration will be dependent on the volume of filler that has flowed along the artery and the resulting homogeneity of the central retinal artery blockage. If sufficient volume and pressure of the filler is injected, the entire ophthalmic artery may become occluded. Occlusion of the ophthalmic artery will result in ischaemia to the anatomical structures of the orbit including ocular rectus muscles for eye movement. This is characterised by visual loss coupled with pain

Although serious adverse events from the use of non-surgical treatments are rare, the consequences can be devastating

and loss of normal ocular movements.³

Necrosis of the skin occurs as a consequence of compromised arterial blood supply to the skin. The injection of filler into an end-artery may result in antero-grade flow and occlusion of the blood vessel. In addition, injection of a sufficient volume of filler near an end-artery may result in compression of the vessel; this may be more likely with a filler that expands after use such as a hydrophilic hyaluronic acid. Compromised arterial supply to the skin results in rapid hypoxia, characterised by blanching of the skin and ischaemic pain.^{12,16}

A very rare complication is a cerebrovascular accident (CVA or stroke) as a consequence of non-surgical hyaluronic acid fillers.¹⁸ This occurs as a consequence of the rich vascular anastomosis between the vascular supply of the face and orbit, retrograde flow of the inadvertent injection of hyaluronic acid material to be forced into the ophthalmic artery and internal carotid artery. Subsequent antero-grade flow of the material in the internal carotid artery is then able to result in blockage of the end arteries to the brain resulting in a CVA.

Facial Danger Zones

On evaluation of both the medical literature for complications related to filler injections and our knowledge of the facial anatomy, we can derive specific areas of the face that are at a higher risk of these potentially devastating adverse events (**Figure 6 & 7**).

Facial danger zones and associated facial arteries:

1. Glabellar area: Supraorbital & Supratrochlear arteries
2. Nasal augmentation: Angular artery
3. Nasolabial groove: Facial artery
4. Tear trough (Nasojugal groove): Infraorbital artery
5. Temporal volume loss: Superficial temporal artery

Treatment of Complications

The treatment of visual loss as a consequence of intra-arterial filler injection and central retinal artery occlusion is challenging. The use of a hyaluronic acid filler warrants the injection of hyaluronidase with the intention of dissolving the filler. Urgent blue light referral to an ophthalmic emergency unit is warranted as failure to take action could result in permanent visual loss. Treatment includes the use of medications to reduce intra-ocular pressure, carbogen treatment to cause vasodilation and hyperbaric oxygen. Cadaver studies have suggested treatment with urgent retro-orbital injection of hyaluronidase into the retro-bulbar orbital space may be effective in the treatment of blindness.¹⁹

The treatment of impending skin necrosis is characterised by an attempt to reverse the end-arterial occlusion and to reduce the resulting inflammatory process that results in soft tissue damage. Treatment with an emergency kit should include hyaluronidase

(only applicable for hyaluronic acid fillers), a nitrate patch or paste, anti-inflammatory medication (oral or intravenous prednisolone: reduce inflammatory damage to the ischaemic soft tissues), vasodilators and hyperbaric oxygen (increase blood supply to the soft tissues reducing ischaemic tissue damage).¹⁶ There is currently limited scientific evidence that supports the use of the different treatment modalities, and the treatment methodology listed is mostly derived from relatively low level scientific evidence including anecdotal evidence and case reports.

Based on the limited information we do have, here are suggestions for an emergency filler kit for treatment of vascular necrosis:

- Hyaluronidase: If hyaluronic acid injected 6-8x 0.05cc of hyaluronidase (150units/ 0.1cc) into the skin (although up to 1,000 units has been advocated) or alternatively into Retro Bulbar Orbital Space (400-800 units injected with 25-gauge needle or cannula into infero-temporal orbital quadrant)¹⁹
- Warm compression and massage
- Nitrate patch or Nitroglycerine paste (for 12 hours)
- Aspirin (Acetylsalicylic acid) 300mg
- Intravenous hydrocortisone 100mg
- Oral dexamethasone 60mg for five days
- Sildenafil (Vascular dilation)
- Hyperbaric oxygen
- Antibiotics (prevent secondary bacterial infection)
- Antivirals (around mouth to prevent secondary viral infection)

Discussion and Prevention of Complications

Although serious adverse events from the use of non-surgical treatments are rare, the consequences can be devastating. They can include blindness, skin necrosis and facial scarring. The treatment of these serious adverse events is both challenging and limited, and prevention of these complications is preferred. There are a number of measures that can be taken to mitigate the risk of a serious complication after non-surgical filler injections. In the first instance this is an understanding of the underlying anatomy and the concept of facial danger zones. On injection of the filler, aspiration of the filler before injection may result in a flash back of blood if the needle is injected into a facial artery – although this method may not be conclusive if there is no flash back, as there may be a collapse of the artery on the pressure of aspiration. A flash back of blood would enable the injector to re-position the needle to an alternative location. From my experience, I have noted that the use of cannulas with blunt-

Key points: prevention of complications

- Knowledge of vascular facial anatomy
- Concept of facial danger zones associated with higher risk of treatment
- Hyaluronic acid product has the advantage of hyaluronidase antidote
- Aspiration needle technique before injection
- Cannula technique over needle technique
- Low pressure injection
- Low volume fractionated technique of injection
- Recognise immediate blanching of skin
- Use of local anaesthesia with adrenaline to cause local vasoconstriction of facial blood vessels
- Emergency filler kit

ended tips is less likely to result in traumatic injury to an arterial wall and can result in the injection of the filler intra-arterially. In my opinion, a low-pressure injection makes an intra-arterial injection less likely, and a low volume of filler injection makes the bolus less likely to result in central retinal artery occlusion. An injection that results in immediate blanching of skin should be treated as vascular compromise and requires urgent treatment (vascular occlusion results in skin hypoxia, the reduced oxygen carriage in the skin results in a change in skin colour). The pre-filler use of local anaesthesia with adrenaline results in local vasoconstriction (reduced diameter of the arteries), reducing the risk of intra-arterial injection. Some injectors prefer filler treatments without the use of adrenaline in the local anaesthesia as this may mask the discolouration caused by intra-arterial injection,¹⁷ making the ischaemia caused by intra-arterial more difficult to see.

Conclusion

The use of non-surgical filler injections for soft tissue augmentation and facial rejuvenation continues to grow and is generally regarded as safe and effective. The adverse events such as the loss of visual function, blindness and skin necrosis, which have been reported, highlight the importance of adequate knowledge in the management and prevention of further serious complications. Knowledge of the underlying anatomy, mechanism, preparation for emergency treatment and steps taken towards prevention are important to ensure that the risk of these events is minimised and appropriate.



Dr Julian De Silva is a facial cosmetic surgeon, specialising in the eyes, nose, face and neck areas. He has experience in cosmetic/reconstructive facial surgery from fellowships in London, LA and New York.

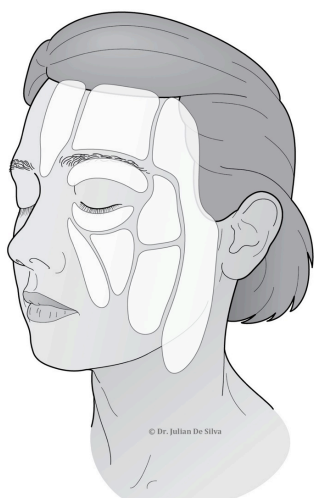

Figure 1: Subcutaneous fat compartments of the face (Rohrich, 2007)¹²

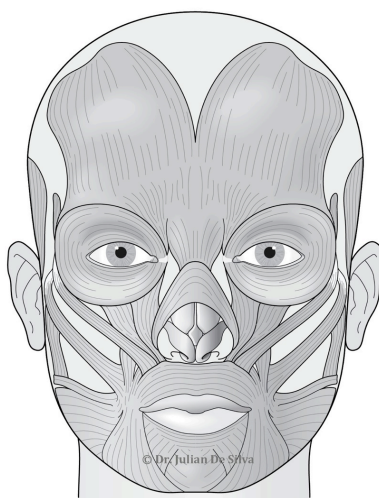


Figure 2: Muscles of facial expression

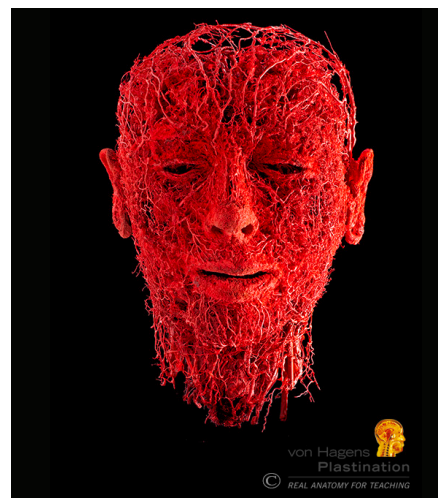

Figure 3: Profuse anastomosis of facial blood vessels courtesy of Prof. Von Hagens 2014.

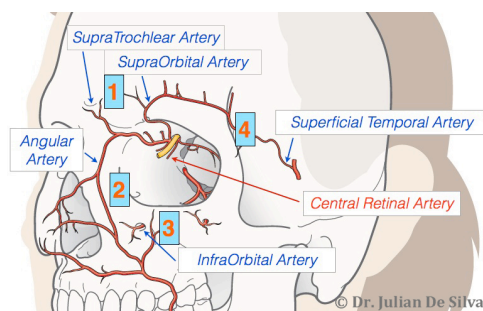


Figure 4: Anastomosis of facial vessels around the eyes

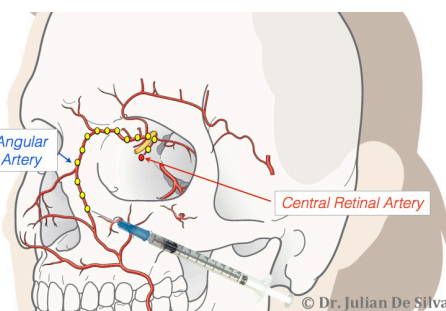


Figure 5: Intra-arterial injection of filler results in retrograde flow of the filler into the ophthalmic artery and the central retinal artery. Occlusion of the central retinal artery results in painless loss of vision.

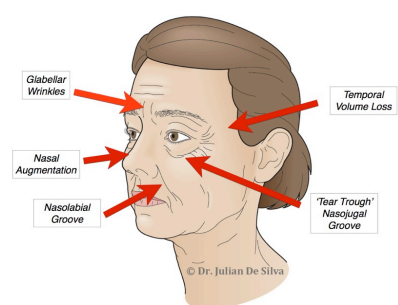


Figure 6: The concept of facial danger zones. Injections of filler into these areas have an increased risk of intra-arterial injection and can result in serious adverse events.

REFERENCES

1. 'Cosmetic Surgery National Data Bank Statistics', (American Society for Aesthetic Plastic Surgery: US, 2103) http://www.surgery.org/sites/default/files/Stats2013_4.pdf Last accessed: 17 December 2014
2. Carle MV, Roe R, Novack R, Boyer DS. 'Cosmetic facial fillers and severe vision loss', *JAMA Ophthalmol*, 5 (2014) p.637-9.
3. Chen Y, Wang W, Li J, Yu Y, Li L, Lu N, 'Fundus artery occlusion caused by cosmetic facial injections', *Chin Med J (Engl)*, 127 (2014) p.1434-7.
4. Yanyun C, Wenying W, Jipeng L, Yajie Y, Lin L and Ning L, 'Fundus artery occlusion caused by cosmetic facial injections', *Chinese Medical Journal*, 127 (2014) p.1434-1437.
5. Kim YJ, Choi KS, 'Bilateral Blindness after Filler Injection', *Plast Reconstr Surg*, 131(2013) p. 298-299.
6. Kim SN, Byun DS, Park JH, Han SW, Baik JS, Kim JY, Park JH, 'Panophthalmoplegia and vision loss after cosmetic nasal dorsum injection', *J Clin Neurosci*, 21 (2014) p.678-80.
7. Lazzeri D, Agostini T, Figus M, Nardi M, Pantaloni M, Lazzeri S, 'Blindness following cosmetic injections into the face', *Plast Reconstr Surg*, 129(2012) p.995-1012.
8. Woo SJ, Park SW, Park KH, Huh W, Jung C, Kwon OK, 'Iatrogenic retinal artery occlusion caused by cosmetic facial filler injections', *American Journal of Ophthalmology*, 154(2012) p.653-662.
9. Lee DH, Yang HN, Kim JC, Shyn KH, 'Sudden unilateral visual loss and brain infarction after autologous fat injection into nasolabial groove', *Br J Ophthalmol*, 80 (1996) p.1026-1027.
10. Egido JA et al., 'Middle cerebral artery embolism and unilateral visual loss after autologous fat injection into the glabellar area', *Stroke*, 24 (1993) p.615-616.
11. Ozturk CN, Li Y, Tung R, Parker L, Piliang MP, Zins JE, 'Complications following injection of soft-tissue fillers', *Aesthet Surg J*, 1 (2013) p.862-77.
12. Funt D, Pavicic T, 'Dermal fillers in aesthetics: an overview of adverse events and treatment approaches', *Clin Cosm Inv Derm* 129(2013) p.295-316.
13. Dayan SH, Arkins JP, Mathison CC, 'Management of impending necrosis associated with soft tissue filler injections', *J Drugs Dermatol JDD*, 10 (2011) p.1007-12.
14. Rohrich RJ, Pessa JE, 'The Fat Compartments of the Face: Anatomy and Clinical Implications for Cosmetic Surgery', *Plast Reconstr Surg*, 119 (2007) p.2219-2227.
15. Kurkjian TJ, Agnad J, Rohrich RJ, 'Soft-Tissue Fillers in Rhinoplasty', *Plast. Reconstr. Surg*, 133 (2014).
16. Tsai M, Hsia T, Han Y, Wu H, Lin Y, 'Successful Hyperbaric Oxygen Therapy In Complications Of Fillers Rhinoplasty Cases Report', *The Internet Journal of Alternative Medicine*, 9 (2014).
17. Emer J, & Waldorf H, 'Injectable neurotoxins and fillers: There is no free lunch', *Clinics in Dermatology*, 29 p.678-690.
18. He MS, Sheu MM, Huang ZL, Tsai CH, Tsai RK, 'Sudden bilateral vision loss and brain infarction following cosmetic hyaluronic acid injection', *JAMA Ophthalmol*, 131 (2013) p.1234-5.
19. Carruthers JD, Fagien S, Rohrich RJ, Weinkle S, Carruthers A, 'Blindness caused by cosmetic filler injection: a review of cause and therapy', *Plast Reconstr Surg*, 134 (2014) p.1197-201.